

## Role of Vascular Endothelial Growth Factor A in Children With Acquired Airway Stenosis

Reza Rahbar, DMD, MD; Lawrence F. Brown, MD; Judah Folkman, MD;  
Trevor J. McGill, MD; Gerald B. Healy, MD; Guanmei Liu, PhD; Sara O. Vargas, MD

**Objectives:** Vascular endothelial growth factor A (VEGF-A) is important in the angiogenic response for wound healing. This study investigated whether VEGF-A may play a role in the pathogenesis of acquired airway stenosis.

**Methods:** Eight lesions from 5 pediatric patients with subglottic stenosis after airway reconstruction (N = 4) or prolonged intubation (N = 1) and normal laryngeal tissue from 5 autopsy patients were included. Formalin-fixed sections of subglottic tissue from each patient were examined by *in situ* hybridization for the presence of messenger RNA (mRNA) for VEGF-A, vascular endothelial growth factor receptor 1 (VEGFR-1), and vascular endothelial growth factor receptor 2 (VEGFR-2).

**Results:** Strong expression of VEGF-A mRNA was noted in hyperplastic squamous epithelium overlying granulation tissue. Strong expression of VEGFR-1 and VEGFR-2 was noted in the endothelial cells within granulation tissue. No strong labeling of VEGF-A mRNA or its receptors was noted in 2 specimens with mature scar tissue or in the control specimens.

**Conclusions:** The angiogenic growth factor VEGF-A is strongly expressed in hyperplastic epithelium overlying granulation tissue in airway stenosis. Also, VEGFR-1 and VEGFR-2 mRNAs are strongly expressed in the endothelial cells of granulation tissue. This finding suggests an important role of VEGF-A in the pathogenesis of airway scar formation and stenosis.

**Key Words:** airway stenosis, angiogenesis, vascular endothelial growth factor A.

### INTRODUCTION

Scar formation with stenosis remains the main cause of failure in airway surgery in both pediatric and adult populations. One of the main components of the wound healing process is angiogenesis. It is possible that modulation of wound healing and decreasing angiogenesis may be effective in decreasing scar formation and increasing the success rate of airway surgery. Recently, a number of studies have shown the role of angiogenesis and different angiogenic growth factors in the pathogenesis of wound healing.<sup>1-3</sup> Vascular endothelial growth factor A (VEGF-A) is known to play a critical role in the angiogenic response essential for wound healing and scar formation outside the respiratory tract.<sup>2,4,5</sup> The goal of our study was to investigate whether VEGF-A and its receptors may play a role in acquired airway scar formation and stenosis.

### MATERIALS AND METHODS

The patients included 5 children who underwent

airway surgery for acquired airway stenosis from 1995 to 2004 at Children's Hospital Boston. All data with respect to age, gender, initial presentation, and location of stenosis were reviewed. Four patients had 1 tissue sample each; 1 patient (an 8-year-old boy who had had airway reconstruction) had 4 laryngeal tissue specimens sampled at 4 different time points. Tissue sections of normal larynges including both respiratory and squamous mucosa from 5 autopsy patients (7 months to 20 years of age; mean, 5 years) without a history of airway stenosis were obtained as controls. This study was performed under an Institutional Review Board-approved protocol.

Light microscopic examination was conducted on formalin-fixed, paraffin-embedded sections stained with hematoxylin and eosin. Eight lesions from the 5 patients were examined. Immunohistochemical staining for the endothelial marker CD31 (BioGenex Laboratories, San Ramon, California) was performed on paraffin-embedded sections by means of a streptavidin-biotin-based alkaline phosphatase

From the Departments of Otolaryngology and Communication Disorders (Rahbar, McGill, Healy), Surgery (Folkman), and Pathology (Vargas), Children's Hospital Boston, and the Department of Pathology, Beth Israel-Deaconess Medical Center (Brown, Liu), Harvard Medical School, Boston, Massachusetts.

Presented at the meeting of the American Broncho-Esophagological Association, Chicago, Illinois, May 19-20, 2006.

**Correspondence:** Reza Rahbar, DMD, MD, Dept of Otolaryngology, Children's Hospital Boston, 300 Longwood Ave, Boston, MA 02115.



detection kit (universal multispecies USA horseradish peroxidase kit, Signet Laboratories, Dedham, Massachusetts) with liquid DAB-plus (Zymed, San Francisco, California) as the chromogen. In situ hybridization was performed on 5- $\mu$ m paraffin sections with antisense probes for VEGF-A, VEGF receptor 1 (VEGFR-1; flt-1), and VEGF receptor 2 (VEGFR-2; KDR) and control sense probes. The in situ hybridization method has been previously published in detail.<sup>6</sup> Briefly, slides were passed through xylene; graded alcohols; 0.2 mol/L HCl; Tris/EDTA with 3  $\mu$ g/mL proteinase K; 0.2% glycine; 4% paraformaldehyde in phosphate-buffered saline solution, pH 7.4; 0.1 mol/L triethanolamine containing 1/200 (vol/vol) acetic anhydride; and 2 $\times$  SSC. Slides were hybridized overnight at 50°C with <sup>35</sup>S-labeled riboprobes in the following mixture: 0.3 mol/L NaCl, 0.01 mol/L Tris pH 7.6, 5 mmol/L EDTA, 50% formamide, 10% dextran sulfate, 0.1 mg/mL yeast tRNA, and 0.01 mol/L dithiothreitol. Posthybridization washes included 2 $\times$  SSC/50% formamide/10 mmol/L dithiothreitol at 50°C; 4 $\times$  SSC/10 mmol/L Tris/1 mmol/L EDTA with 20  $\mu$ g/mL ribonuclease A at 37°C; and 2 $\times$  SSC/50% formamide/10 mmol/L dithiothreitol at 65°C and 2 $\times$  SSC. Slides were then dehydrated through graded alcohols containing 0.3 mol/L ammonium acetate, dried, coated with Kodak NTB 2 emulsion, and stored in the dark at 4°C for 2 weeks. The emulsion was developed with Kodak D19 developer, and the slides were counterstained with hematoxylin. Antisense 204 bp single-stranded <sup>35</sup>S-labeled VEGF-A RNA probe and its sense control have been described previously.<sup>7</sup> The antisense probe hybridizes specifically with a region of VEGF-A messenger RNA (mRNA) common to all known splicing variants. <sup>35</sup>S-labeled single-stranded antisense probes targeted to VEGF-A receptors 1 and 2 have been described previously.<sup>8</sup>

## RESULTS

In all 5 patients, the diagnosis of airway stenosis was confirmed on the basis of endoscopic and histopathologic findings. The patients presented with stridor and subglottic stenosis after airway reconstruction (N = 4) or prolonged intubation (N = 1). There were 3 boys and 2 girls with a mean age of 6 years (range, 11 months to 9 years).

Histologic examination in 6 of the 8 lesions showed active granulation tissue with abundant small blood vessels (Fig 1A). A polypoid configuration was appreciable in 2 of these. Squamous epithelium overlay the granulation tissue in 2 of these cases, and the epithelium was denuded in 4; ciliated respiratory epithelium was not observed. Two cases lacked active granulation tissue and showed well-

established collagenized fibrous tissue with overlying squamous epithelium (Fig 1B). CD31 staining highlighted prominent vascularity in the granulation tissue and sparse vascularity in the more well-established fibrous tissue.

Strong expression of VEGF mRNA was detected in hyperplastic squamous epithelium overlying the granulation tissue (Fig 2A,B). Expression of VEGF-A was strongest in the suprabasal epithelial levels. (The basal layer is seen in the lower right part of Fig 2A.) No specific labeling was seen with the control sense probe. Strong expression of mRNAs for the VEGF-A receptors VEGFR-1 and VEGFR-2 was detected in endothelial cells of the prominent blood vessels (arrows) in the active granulation tissue of the subglottic stenosis (Fig 2C-F). The 2 cases with mature scar tissue showed sparse vascularity, highlighted by CD31 immunostaining. These lesions lacked strong expression of VEGF-A and receptor mRNAs.

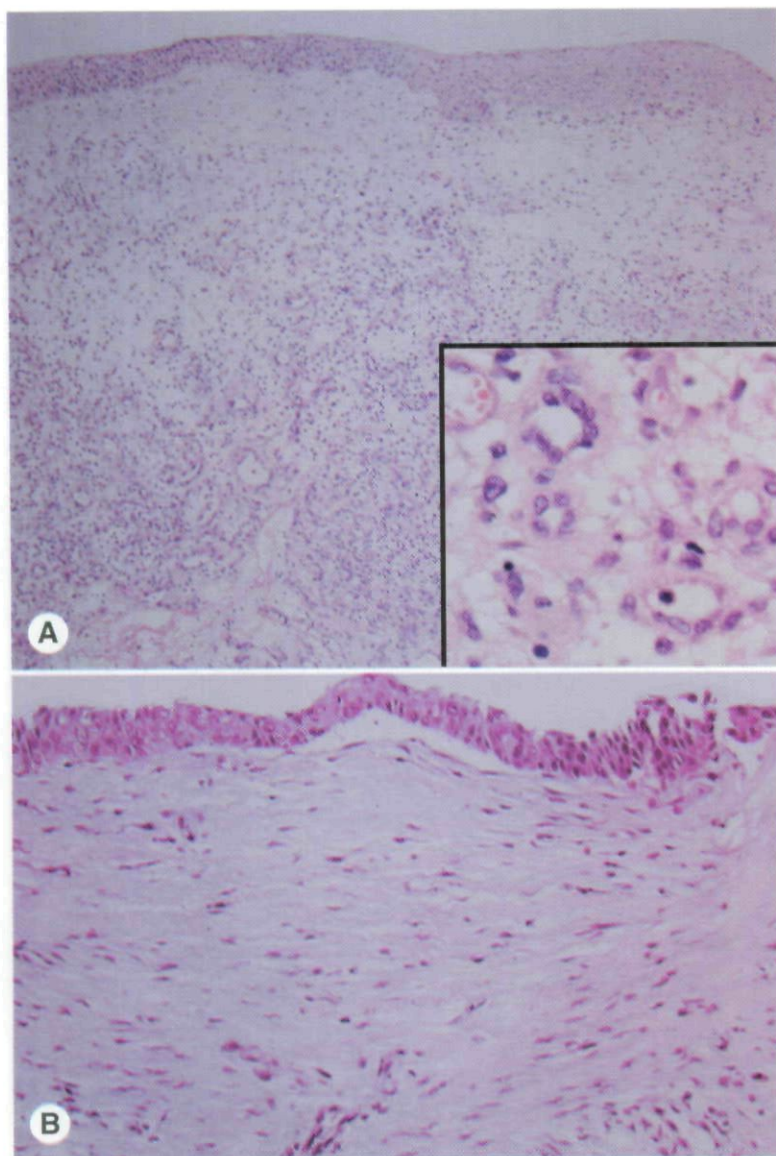
Histologic examination of 5 autopsy control patients showed unremarkable squamous and respiratory mucosa, without any evidence of granulation tissue or fibrosis. Immunohistochemical analysis and in situ hybridization studies were performed on the 5 control laryngeal biopsies. No increased vascularity was noted with CD31 immunostaining. No strong expression of VEGF mRNA or its receptors was seen in any of the control patients (Fig 2).

## DISCUSSION

Treatment of airway stenosis in both pediatric and adult populations remains one of the most difficult challenges in our specialty. Despite advancements in both open and endoscopic approaches to the management of airway stenosis, there is still a high degree of scar formation and restenosis. In the past 2 decades, there has been a surge of interest in using different pharmacologic agents to reduce the degree of scar formation and increase the success rate of airway surgery. Adjuvant treatments with agents such as 5-fluorouracil,  $\beta$ -aminopropionitrile, corticosteroid, and mitomycin C have been used with some success.<sup>1,9-12</sup>

The causes of acquired airway stenosis include conditions such as prolonged intubation, airway surgery, and other trauma. The histopathologic features of endotracheal intubation-induced injury and stenosis have been well described.<sup>13-17</sup> The process occurs predominantly in the subglottic region, which is thought to be most susceptible because it is the site with the smallest diameter and it is bounded most fully by cartilage. Authors have proposed a sequence of events leading to stenosis that includes





**Fig 1. A)** Granulation tissue with exuberant vascularization and overlying squamous epithelium (original  $\times 10$ ). **Inset)** Original  $\times 60$ . **B)** Fibrosis with increased collagenization and diminished vascularization (original  $\times 20$ ).

ulceration and necrosis of airway mucosa and/or cartilage, inflammatory reaction and granulation tissue formation, fibrous scarring, and contracture.<sup>13</sup> The pathologic features of stenosis following airway reconstructive surgery are not as well characterized, but presumably involve a similar sequence of events.

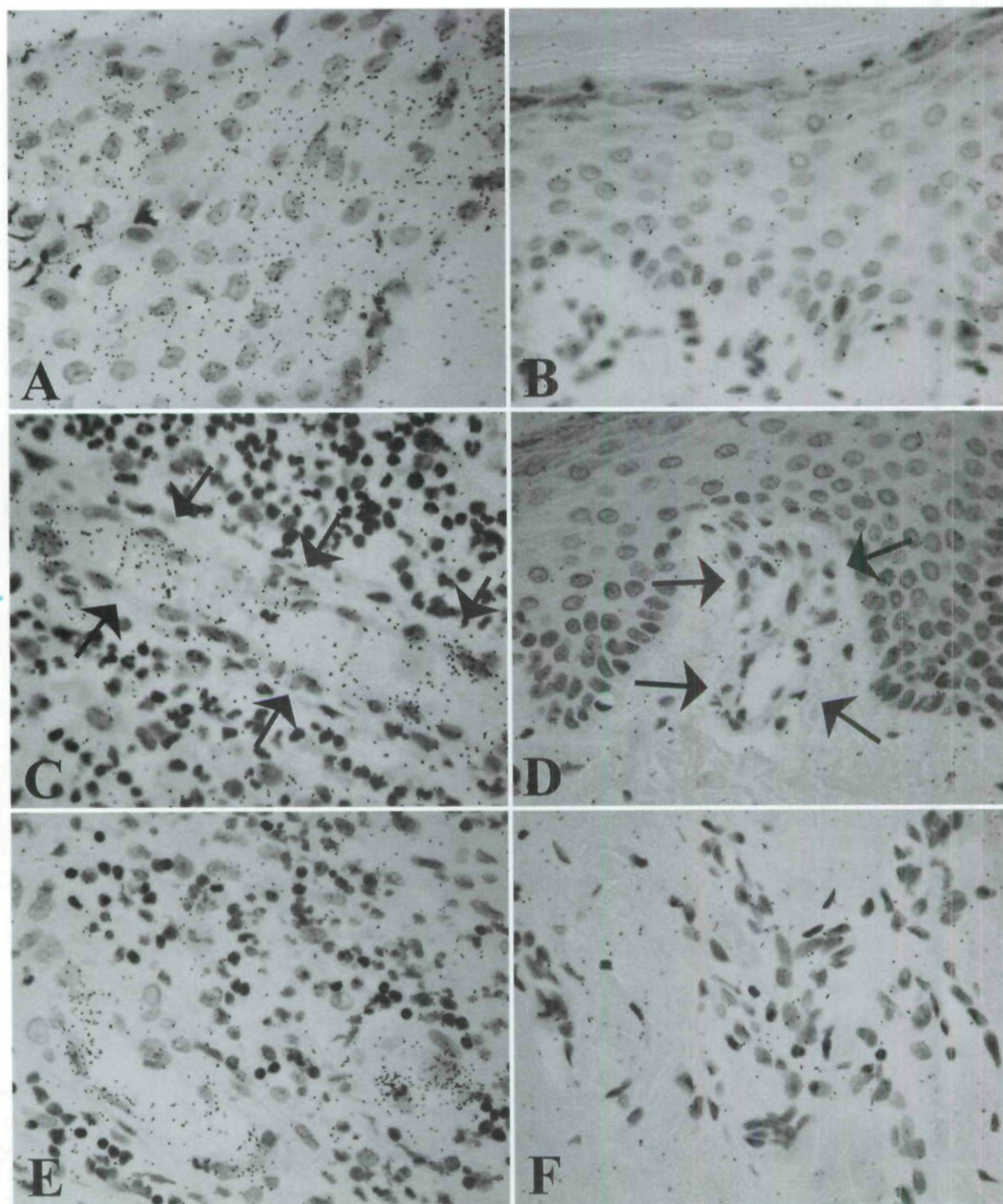
Healing injury in the upper airway shows many features analogous to granulation tissue and wound repair at other body sites, but there are several aspects unique to the site that may account for differences. Airway mucosa is in direct approximation with perichondrium and cartilage, which typically show damage in subglottic stenosis; cartilage injury has been proposed to lead to a particularly vigorous scarring response.<sup>13,15,18</sup> We speculate that this may relate to the compounding of VEGF expression, which is known to increase in ischemic and/or

hypoxic cartilage.<sup>19,20</sup>

An airway mucosal wound with vascular damage leads to bleeding and hyperpermeability, which involves a release of plasma proteins, blood cells, and platelets, which react with tissue factor to form a fibrin clot.<sup>11,21</sup> This serves as a matrix for the migration of inflammatory cells and activated fibroblasts and endothelial cells. Compromise of mucosal blood vessels and resultant ischemia and/or infarction may also provoke granulation tissue formation; for example, "pressure necrosis" is thought to occur in postintubation subglottic stenosis because of the compression of blood vessels against nonresilient cartilage.<sup>22</sup>

Recently, there has been an interest in the role of angiogenesis and angiogenic growth factors in wound healing and scar formation in different disease processes. A number of investigators have re-





**Fig 2.** In situ hybridization. Strong labeling with vascular endothelial growth factor A (VEGF-A) antisense probe indicates strong epithelial VEGF-A expression in squamous epithelium in subglottic stenosis (A; basal layer is at lower right), but not in control (B). Strong VEGF receptor expression is seen in endothelial cells (arrows) in subglottic stenosis (C, VEGFR-1; E, VEGFR-2), but not in control tissue (D, VEGFR-1; F, VEGFR-2).

ported the role of peptide growth factors in conditions such as pulmonary fibrosis, hepatic cirrhosis, systemic sclerosis, and nephrosclerosis.<sup>1,2,5</sup> The role of growth factors such as platelet-derived growth factor, transforming growth factor  $\beta$ 2, and epidermal growth factor in the pathogenesis of subglottic stenosis has also been investigated.<sup>3</sup>

The purpose of our study was to evaluate the role of VEGF-A and its receptors, VEGFR-1 and VEGFR-2, in airway stenosis. VEGF-A exerts a variety of effects on vascular endothelium. It is among the most potent vascular permeabilizing agents known, with a potency that is 50,000 times that of histamine.<sup>23</sup> After exposure to VEGF-A, the earliest



biological effect is increased vascular permeability, which is noted within seconds to minutes.<sup>23</sup> Other delayed reactions include changes in endothelial cell shape, migration, adhesion, and altered mRNA and protein expression that occur hours to weeks after exposure.<sup>23,24</sup>

VEGF-A actions are mediated through 2 high-affinity receptors, VEGFR-1 and VEGFR-2.<sup>23,24</sup> The fact that both of these receptors are expressed predominantly on vascular endothelium would explain the strong selectivity of VEGF-A on endothelial cells. VEGF-A increases vascular permeability, leading to extravasation of plasma proteins and pro-angiogenic stromal changes.<sup>25,26</sup> VEGF-A is also an endothelial cell mitogen promoting angiogenesis in the endothelial cells.<sup>25,26</sup>

VEGF-A and its receptors have been shown to play a role in a number of normal physiologic, inflammatory, and neoplastic processes.<sup>27-29</sup> The role of VEGF-A in promoting angiogenesis in conditions such as delayed hypersensitivity, retinopathies, rheumatoid arthritis, and inflammatory skin disorders has been reported.<sup>30-32</sup> The role of VEGF-A in the pathogenesis of different neoplastic disorders has also been of interest. Overexpression of VEGF-A and its receptors has been shown in breast cancer, bladder carcinomas, gastrointestinal adenocarcinomas, cutaneous angiosarcoma, and Kaposi's sarcoma.<sup>8,33-35</sup>

The role of VEGF-A in wound healing has also been investigated. In 1992, Brown et al<sup>4</sup> showed that expression of VEGF-A mRNA increases dramatically in the epidermal keratinocytes at the wound edge and in residual hair follicles at the wound base during the first 24 hours after a skin wound. Their study showed that VEGF-A overexpression reaches

a peak at 2 days and persists at an elevated level for 1 week, the time required for granulation tissue to form and keratinocytes to cover the wound defect.<sup>4</sup> In 1993, Peters et al<sup>36</sup> reported an increased expression of VEGF receptors in the endothelial cells lining the new blood vessels in the developing granulation tissue of healing wounds. An increase in microvascular hyperpermeability due to overexpression of VEGF-A during the early phase of wound healing has also been reported.<sup>37</sup> One previous study has examined expression of VEGF in tracheal granulation tissue in children with histories of surgical airway repair; using immunohistochemistry and in situ hybridization, the authors demonstrated that VEGF expression was increased in comparison with normal tracheal epithelial cells.<sup>38</sup>

Our examination was limited by the nature of human subject study. Unlike animal model studies, in which all phases of injury can be assessed, our human study included tissue that was not accessible until the injury had reached the granulation tissue-fibrosis stage of healing, at which time tissue resection was dictated by patients' symptoms. A further limitation of the study is that it included only pediatric patients.

This study is the first to evaluate the role of both VEGF-A and its receptors in acquired airway stenosis. We have found markedly increased expression of VEGF-A mRNA and its receptors in granulation tissue of our patients with subglottic stenosis. According to our study and other reports, this may have a direct effect on the amount of granulation tissue and subsequent scar formation. It is our belief that inhibition of VEGF-A or its receptors may lead to decreased scar formation and thereby minimize restenosis in the airway.

#### REFERENCES

1. Border WA, Ruoslahti E. Transforming growth factor- $\beta$  in disease: the dark side of tissue repair. *J Clin Invest* 1992;90:1-7.
2. Czaja MJ, Weiner FR, Flanders KC, et al. In vitro and in vivo association of transforming growth factor- $\beta$ 1 with hepatic fibrosis. *J Cell Biol* 1989;108:2477-82.
3. Scioscia KA, April MM, Miller F, Gruber BL. Growth factors in subglottic stenosis. *Ann Otol Rhinol Laryngol* 1996;105:936-43.
4. Brown LF, Yeo K-T, Berse B, et al. Expression of vascular permeability factor (vascular endothelial growth factor) by epidermal keratinocytes during wound healing. *J Exp Med* 1992;176:1375-9.
5. Kulozik M, Hogg A, Lankat-Buttgereit B, Krieg T. Colocalization of transforming growth factor- $\beta$ 2 with alpha 1(I) procollagen mRNA in tissue sections of patients with systemic sclerosis. *J Clin Invest* 1990;86:917-22.
6. Ffrench-Constant C, Van de Water L, Dvorak HF, Hynes RO. Reappearance of an embryonic pattern of fibronectin splicing during wound healing in the adult rat. *J Cell Biol* 1989;109:903-14.
7. Brown LF, Berse B, Tognazzi K, et al. Vascular permeability factor mRNA and protein expression in human kidney. *Kidney Int* 1992;42:1457-61.
8. Brown LF, Berse B, Jackman RW, et al. Expression of vascular permeability factor (vascular endothelial growth factor) and its receptors in adenocarcinomas of the gastrointestinal tract. *Cancer Res* 1993;53:4727-35.
9. Doolin EJ, Strande LF, Tsuno K, Santos MC. Pharmacologic inhibition of collagen in an experimental model of subglottic stenosis. *Ann Otol Rhinol Laryngol* 1998;107:275-9.
10. Rahbar R, Shapshay SM, Healy GB. Mitomycin: effects on laryngeal and tracheal stenosis, benefits, and complications. *Ann Otol Rhinol Laryngol* 2001;110:1-6.
11. Rahbar R, Jones DJ, Nuss RC, et al. The role of mitomycin in the prevention and treatment of scar formation in the



pediatric aerodigestive tract: friend or foe? Arch Otolaryngol Head Neck Surg 2002;128:401-6.

12. Ingrams DR, Ashton P, Dhingra J, Shah R, Shapshay SM. Slow-release 5-fluorouracil and triamcinolone reduces subglottic stenosis in a rabbit model. Ann Otol Rhinol Laryngol 2000; 109:422-4.

13. Liu H, Chen JC, Holinger LD, Gonzalez-Crussi F. Histopathologic fundamentals of acquired laryngeal stenosis. Pediatr Pathol Lab Med 1995;15:655-77.

14. Fechner RE, Cooper PH, Mills SE. Pyogenic granuloma of the larynx and trachea. A causal and pathologic misnomer for granulation tissue. Arch Otolaryngol 1981;107:30-2.

15. Duynstee ML, de Krijger RR, Monnier P, Verwoerd CD, Verwoerd-Verhoef HL. Subglottic stenosis after endolaryngeal intubation in infants and children: result of wound healing processes. Int J Pediatr Otorhinolaryngol 2002;62:1-9.

16. Chen JC, Holinger LD. Acquired laryngeal lesions. Pathologic study using serial macrosections. Arch Otolaryngol Head Neck Surg 1995;121:537-43.

17. Gould SJ, Young M. Subglottic ulceration and healing following endotracheal intubation in the neonate: a morphometric study. Ann Otol Rhinol Laryngol 1992;101:815-20.

18. Quiney RE, Gould SJ. Subglottic stenosis: a clinicopathological study. Clin Otolaryngol Allied Sci 1985;10:315-27.

19. Kim HK, Bian H, Randall T, Garces A, Gerstenfeld LC, Einhorn TA. Increased VEGF expression in the epiphyseal cartilage after ischemic necrosis of the capital femoral epiphysis. J Bone Miner Res 2004;19:2041-8.

20. Lin C, McGough R, Aswad B, Block JA, Terek R. Hypoxia induces HIF-1 $\alpha$  and VEGF expression in chondrosarcoma cells and chondrocytes. J Orthop Res 2004;22:1175-81.

21. Tahery MM, Lee DA. Review: pharmacologic control of wound healing in glaucoma filtration surgery. J Ocul Pharmacol 1989;5:155-79.

22. Reidenbach MM, Schmidt HM. Anatomical aspects of postintubational subglottic stenosis. Clin Anat 1995;8:273-80.

23. Dvorak HF, Nagy JA, Feng D, Brown LF, Dvorak AM. Vascular permeability factor/vascular endothelial growth factor and the significance of microvascular hyperpermeability in angiogenesis. Curr Top Microbiol Immunol 1999;237:97-132.

24. Rahbar R, Vargas SO, Folkman J, et al. Role of vascular endothelial growth factor-A in recurrent respiratory papillomatosis. Ann Otol Rhinol Laryngol 2005;114:289-95.

25. Brown LF, Guidi AJ, Schnitt SJ, et al. Vascular stroma formation in carcinoma in situ, invasive carcinoma, and metastatic carcinoma of the breast. Clin Cancer Res 1999;5:1041-56.

26. Pepper MS, Ferrara N, Orci L, Montesano R. Vascular

endothelial growth factor (VEGF) induces plasminogen activators and plasminogen activator inhibitor-1 in microvascular endothelial cells. Biochem Biophys Res Commun 1991;181:902-6.

27. Brown LF, Berse B, Jackman RW, et al. Expression of vascular permeability factor (vascular endothelial growth factor) and its receptors in breast cancer. Hum Pathol 1995;26:86-91.

28. Folkman J, Shing Y. Angiogenesis. J Biol Chem 1992; 267:10931-4.

29. Bovee JV, van den Broek LJ, de Boer WI, Hogendoorn PC. Expression of growth factors and their receptors in adamantinoma of long bones and the implication for its histogenesis. J Pathol 1998;184:24-30.

30. Pierce EA, Avery RL, Foley ED, Aiello LP, Smith LE. Vascular endothelial growth factor/vascular permeability factor expression in a mouse model of retinal neovascularization. Proc Natl Acad Sci U S A 1995;92:905-9.

31. Fava RA, Olsen NJ, Spencer-Green G, et al. Vascular permeability factor/endothelial growth factor (VPF/VEGF): accumulation and expression in human synovial fluids and rheumatoid synovial tissue. J Exp Med 1994;180:341-6.

32. Detmar M, Brown LF, Claffey KP, et al. Overexpression of vascular permeability factor/vascular endothelial growth factor and its receptors in psoriasis. J Exp Med 1994;180:1141-6.

33. Brown LF, Berse B, Jackman RW, et al. Increased expression of vascular permeability factor (vascular endothelial growth factor) and its receptors in kidney and bladder carcinomas. Am J Pathol 1993;143:1255-62.

34. Brown LF, Tognazzi K, Dvorak HF, Hristova TJ. Strong expression of kinase insert domain-containing receptor, a vascular permeability factor/vascular endothelial growth factor receptor in AIDS-associated Kaposi's sarcoma and cutaneous angiosarcoma. Am J Pathol 1996;148:1065-74.

35. Senger DR, Galli SJ, Dvorak AM, Perruzzi CA, Harvey VS, Dvorak HF. Tumor cells secrete a vascular permeability factor that promotes accumulation of ascites fluid. Science 1983;219:983-5.

36. Peters KG, De Vries C, Williams LT. Vascular endothelial growth factor receptor expression during embryogenesis and tissue repair suggests a role in endothelial differentiation and blood vessel growth. Proc Natl Acad Sci U S A 1993;90:8915-9.

37. Brown LF, Van de Water L, Harvey VS, Dvorak HF. Fibrinogen influx and accumulation of cross-linked fibrin in healing wounds and in tumor stroma. Am J Pathol 1988;130:455-65.

38. Pokharel RP, Maeda K, Yamamoto T, et al. Expression of vascular endothelial growth factor in exuberant tracheal granulation tissue in children. J Pathol 1999;188:82-6.

Copyright of *Annals of Otolaryngology, Rhinology & Laryngology* is the property of Annals Publishing Company and its content may not be copied or emailed to multiple sites or posted to a listserv without the copyright holder's express written permission. However, users may print, download, or email articles for individual use.